

## ABSTRACT

Some neglected parasitic larvae and worms may cause rare human infections. They are mostly zoonotic species. **Sparganosis** is the infection with a plerocercoid larva of an animal diphylobothriid cestode. The valid species incriminated in causing human sparganosis are *Spirometra erinaceieuropaei*, *Spirometra decipiens*, *Spirometra mansonioides*, *Spirometra theileri*, and the aberrant *Sparganum proliferum*. Other species reported to infect human in the literature are probably nonspecific. **Coenuriasis** is the infection with a metacestode of *Taenia* species, mainly *T. multiceps* or *T. serialis*. **Acanthocephaliasis**, on the other hand, is the infection with acanthocephalan worms. Man was reported to be infected with at least nine acanthocephalan species, among them, *Macracanthorhynchus hirudinaceus* and *Moniliformis moniliformis* are the most common species. **Hirudiniasis** is the human attack by leeches. They are temporary parasites because they attack victims only when they are hungry and drop off when they are engorged. Among all species of leeches, only true leeches especially jawed leeches are known to attack humans. These species are either freshwater or land dwellers. This review summarizes current knowledge of the public health significance of human affections by these parasites, and the recommended methods of prevention and control.

**Keywords:** acanthocephaliasis, coenuriasis, hirudiniasis, neglected parasitic infections, sparganosis.

**Received:** 23 March, 2020, **Accepted:** 24 April, 2020.

**Corresponding Author:** Wael M Lotfy, **Tel.:** +20 1008154959, **E-mail:** waelotfy@mau.edu.eg

**Print ISSN:** 1687-7942, **Online ISSN:** 2090-2646, **Vol. 13, No. 1, April, 2020.**

### Part I - Sparganosis

Human sparganosis is a zoonotic infection with a plerocercoid larva of an animal diphylobothriid cestode. Thus, man acts as a second intermediate host. Unfortunately, only fragmentary and sometimes controversial information about the disease are available in the literature.

**Keywords:** cestoda, flatworms, plerocercoid, public health, sparganum, *Spirometra*.

The term sparganum (plural spargana) is a generic name that refers to any plerocercoid larva. However, it is believed that the causative agents are species of the genus *Spirometra*, as well as the aberrant *Sparganum proliferum*. The plerocercoid larva of *Spirometra* spp. is a wrinkled, whitish, ribbon-shaped motile parasite, a few millimetres in width and up to several centimetres long resembling the narrow tapeworm proglottids. The anterior end of the sparganum is capable of invagination and bears preliminary signs of the sucking grooves formed on the scolex of the adult worm but has no suckers or hooklets. The most common localization of sparganum is the subcutaneous tissue. However, ocular, visceral and cerebral sparganosis have been reported. *Sparganum proliferum* is a branched proliferating larva characterized by a peculiar budding type of larvae that may break up into segments capable of further independent development. This type of larvae may occur almost anywhere in the human body<sup>[1,2]</sup>. Sparganosis may be misdiagnosed as a tumour and *vice versa*<sup>[3-6]</sup>.

Human sparganosis is cosmopolitan, with the highest prevalence rates reported from South Korea, Japan, Thailand, and China<sup>[7-10]</sup>.

### 1. Genus *Spirometra* (Mueller, 1937)

**Synonyms:** Gatesius Stiles, 1908; and Lueheella (Lueheella) Baer, 1924.

The genus was established under the name *Spirometra* by Mueller in 1937<sup>[11]</sup>. Although this name was used by Faust *et al.* in 1929<sup>[12]</sup> as a subgenus, some authors synonymized the genera *Spirometra* and *Diphylobothrium*<sup>[13]</sup>. Phylogenetic results confirmed that the genus *Spirometra* is clearly separate from the genus *Diphylobothrium*<sup>[14]</sup>. *Spirometra* occurs worldwide, although most human cases were recorded from the Southeast Asian countries<sup>[15]</sup>. Some cases were diagnosed in East Africa<sup>[16-22]</sup> and the Americas<sup>[23-29]</sup>, and a few others in Europe mainly from Italy<sup>[30-36]</sup>.

The plerocercoids of the different species of *Spirometra* were described from a variety of animals such as amphibians, reptiles, birds, and mammals including man (Figure 1). Adults were found in carnivores, mainly canines and felines. These animals pass embryonated eggs containing coracidia in their faeces. To complete the life cycle, the parasite must infect two intermediate hosts. The first host is a cyclopoid copepod which ingests the aquatic ciliated hexacanth coracidium. The parasite develops in the copepod tissues into the first larva which is called

proceroid. When the infected crustacean is ingested, the second larval stage, plerocercoid, develops in the second vertebrate intermediate host, which may be an amphibian, reptile, bird, small rodent, primate, or pig<sup>[37]</sup>.

Human accidentally serves as the second intermediate or paratenic host. In most cases, human acts as a dead-end host. Human sparganosis can be acquired through drinking water containing copepods harbouring the proceroid stage. An additional mean for acquiring the infection is ingestion of insufficiently cooked infected amphibians, reptiles, birds, or mammals such as pigs, which contain the plerocercoid stage. A third way of infection is application of infected frog or snake flesh as a poultice on the skin or eyes, where the larvae are activated by warmth and enter the human tissue. Using frog or snake flesh for treatment of skin ulcers and eye inflammation is common in traditional medicine of the Far East<sup>[38]</sup>, and some areas of South America<sup>[29]</sup>. In the human body, larvae form slow-growing migratory nodular lesions. Nodules are mainly found in the subcutaneous tissues of the anterior chest, the abdominal wall, or the inguinal region. Occasionally larvae migrate into unexpected sites of the body such as the pleural cavity<sup>[39]</sup>, or the central nervous system<sup>[40]</sup>, causing unusual or even fatal manifestations. Symptoms of sparganosis depend on the site of infection. Subcutaneous sparganosis presents with a cyst like, itchy, migratory nodule. It is slowly growing and may not be tender. Peripheral blood eosinophilia may be present<sup>[41]</sup>. In ocular sparganosis, the eyelids are oedematous, itchy, and painful with excessive lacrimation, and a cystic nodule is present in the eyelids<sup>[42-44]</sup>.

Diagnosis is made after surgical removal of nodules and identifying the characteristic larva present in an eosinophilic granulomatous reaction<sup>[45]</sup>. Many species of *Spirometra* have been described from various areas of the world as causative agents of human sparganosis. However, the species position is still very confused.

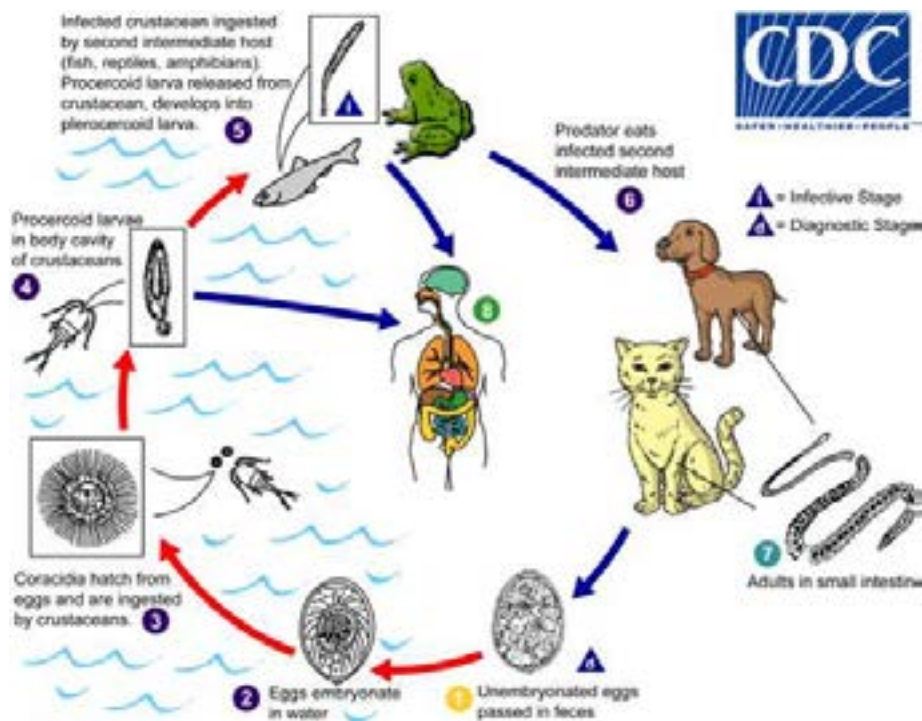
**1.1. *Spirometra erinaceieuropaei* (Rudolphi, 1819) Mueller, 1937.**

**Synonyms:** *Spirometra mansonii* Cobbold, 1882; *Spirometra erinacei* (Rudolphi, 1819) Faust, Campbell, et Kellogg, 1929; *Spirometra houghtoni* Faust, Campbell, et Kellogg 1929; *Spirometra ranarum* Meggitt, 1925.

In 1959, Yamaguti confirmed that *S. mansonii* and *S. erinacei* are synonymous and placed them under the name *S. erinaceieuropaei*<sup>[46]</sup>. This species is the most common cause of human sparganosis in the world. Most cases were reported from the Far East. Probably this species is responsible for the human cases in Europe<sup>[37]</sup>. The plerocercoids acquired orally by man do not develop in the intestine but penetrate the intestinal wall and go through various organs causing sparganosis. Therefore, the adults of *S. erinaceieuropaei* normally do not occur in man. However, on very rare occasions, adult worms were recovered from the intestine of man<sup>[47-49]</sup>. It was suggested that certain altered chemical or enzymatic environment of human gut might be responsible for the unusual adult infection<sup>[37]</sup>.

**1.2. *Spirometra decipiens* Faust, Campbell, et Kellogg, 1929**

In 1929, Faust and co-authors recovered specimens identified as *S. decipiens* from a cat, a leopard, and a dog in China. They obtained the same adult worms



**Fig 1.** The life cycle of *Spirometra* spp., and transmission of human sparganosis (source: <https://www.cdc.gov>).

by feeding larvae from frogs to dogs<sup>[12]</sup>. Only in 2015, human cases infected with this species were confirmed in Korea<sup>[49]</sup>. The identity of the species was confirmed by using morphological and molecular data<sup>[50-52]</sup>. Differentiating morphologic criteria described a spirally coiled uterus with 4.5 coils in *S. decipiens* and 5-7 coils in *S. erinaceiropaei*, while differentiating molecular criteria based on *cox1* gene sequence showed a 1:2 prevalence respectively in human patients in Korea<sup>[50]</sup>. In addition comparison of the mitochondrial genome differentiated between the two species<sup>[51]</sup>. In another study to differentiate spargana from snakes collected from Korea and China revealed the predominance of *S. decipiens* using a multiplex PCR assay (n=854) and phylogenetic analysis of mitochondrial *cox1* sequence (n=50)<sup>[52]</sup>.

### 1.3. *Spirometra mansonoides* (Mueller, 1935) Wardle, McLeod, et Stewart, 1947.

This species is found exclusively in the Americas. When the organism was discovered by Mueller in 1935, he did not know if *S. mansonoides* and *S. erinaceiropaei* were two distinct species<sup>[53]</sup>. In 1974, Mueller distinguished *S. mansonoides* distributed in North America from *S. erinaceiropaei* distributed in Asian region<sup>[54]</sup>. PCR-RFLP analysis of the two worms showed the two to be separate but closely related parasites<sup>[55]</sup>. Experimental human infection with this species was successful<sup>[53]</sup>. A second case of human infection was reported by Read in 1952 in South Texas<sup>[23]</sup>. Since that time many cases were reported<sup>[24,27,28]</sup>.

### 1.4. *Spirometra theileri* (Baer, 1925) Opuni et Muller, 1974

A few cases of human sparganosis were recorded in East Africa<sup>[16-22]</sup>. Most probably these cases were infected with *S. theileri*. The lifecycle of this species is summarized by the presence of the plerocercoids in wild herbivores and adults in large carnivores. The Masai are a semi-nomadic Nilotic ethnic group found in Kenya and northern Tanzania. They are among the best known African ethnic groups because of their distinctive customs and cloth, and residence near the game parks of East Africa. Like wild animals, they move across the plains of East Africa drinking from the same water holes. Sparganosis may be more common in the Masai than has been reported<sup>[21]</sup>. It was identified as the only occasional chronic nodule diagnosed on excision in the Masai<sup>[56]</sup>. Nelson *et al.*<sup>[20]</sup> mentioned that human may be a suitable intermediate host of the parasite because Masai's dead bodies are usually laid out to be eaten by hyenas<sup>[20]</sup>.

### Genus *Sparganum* Diesing, 1854

#### *Sparganum proliferum* (Ijima, 1905) Stiles, 1906

Adults of this parasite have never been found and experimental infections of potential definitive hosts failed. It was assumed that this worm is an aberrant form of *S. erinaceiropaei* or *S. mansonoides*<sup>[37]</sup>. Also,

it was suggested that *S. proliferum* might be a group of proliferating larvae of different species<sup>[57]</sup>. Molecular data suggest that it may be a distinct species of *Spirometra*; however, the adult stage remains unknown<sup>[14,58]</sup>, and the biological features of the proliferating sparganum, including its taxonomic status, are still obscure. Partial sequencing of the mitochondrial cytochrome c oxidase subunit I (*cox1*) gene from several isolates in Asian countries and evaluation of intraspecific variation of *S. erinaceiropaei* and its phylogenetic relationship with *Diphyllobothrium*, confirmed that *S. proliferum* is a distinct species from *S. erinaceiropaei*<sup>[14]</sup>. This was proved in an earlier study also investigating the *cox1* gene and the partial nucleotide sequences of nuclear coded succinate dehydrogenase iron-sulfur protein subunit gene (*sdhB*), and in addition the study confirmed that *S. proliferum* belongs to the order Pseudophyllide<sup>[58]</sup>. Since its first case report by Ijima in 1905 and till 2009, at least 16 well-documented cases of human proliferating sparganosis were reported worldwide. Cases were reported from the Far East and the Americas<sup>[57,59-65]</sup>. This sparganum seems to reproduce inside the host and thus has been called *S. proliferum* or the proliferating sparganum. In humans, it could proliferate with more than one plerocercoid in one lesion and spread to other parts of the body. Thus, at autopsy many thousands of larvae may be present in the viscera as well as in the subcutaneous tissues. Most cases were fatal<sup>[57,60,62,63]</sup>. Disseminated proliferating sparganum was reported as an opportunistic infection in an AIDS patient<sup>[66]</sup>.

In 1968, a human case of Hodgkin disease died after repeated courses of cytotoxic chemotherapy and radiotherapy. The post-mortem examination of the man indicated that an impossible to miss parasite had multiplied and spread all through his body. The shape and structure of the parasite favoured the diagnosis as an aberrant sparganum showing uncontrolled proliferation and spread<sup>[67]</sup>. Afterward, it was described as indistinguishable from *Rodentolepis nana* (*Hymenolepis nana*) in the aberrant larval form<sup>[68]</sup>. More lately, the parasite was identified as a larval cestode with a previously uncharacterized 18S rDNA sequence. It was suggested that it could be a common cestode of a nonhuman, perhaps avian, host and an uncommon human disease agent<sup>[69]</sup>.

### Sparganosis as an emerging human disease

Human sparganosis should be considered among the emerging parasitic infections of increasing concern<sup>[70,71]</sup>. Such emergence may be due to intensive human travelling and migration. Sparganosis was reported in individuals who travelled to endemic regions or who migrated from endemic to non-endemic countries<sup>[72]</sup>. Additionally, there is an increasing trend of human consumption of some unusual animal species, like frogs and snakes<sup>[10]</sup>, which led to increased international trade and intensification of husbandry

practice of these animal species<sup>[70]</sup>. Also, this emergence may be explained by the improvement of the diagnostic methods which favoured additional reporting<sup>[73]</sup>.

### Prevention and control

In endemic foci, people should be advised to avoid drinking water that has not been filtered or treated. People should, also, make sure that flesh that might contain spargana is properly cooked. The use of raw flesh of potentially infected animals in traditional poultices must be discouraged<sup>[1]</sup>.

Surgical removal is the best treatment for human sparganosis. Nevertheless, it is possible only in case of infection with one or a few spargana. The whole body of the spargana should be removed, as any remaining scolex will result in regeneration of the parasite and disease recurrence. Repeated serological tests can confirm removal of the whole sparganum<sup>[74]</sup>. Localised treatment with 40% ethanol procaine or  $\alpha$ -chymotrypsin is used if surgical removal does not work<sup>[75]</sup>. In addition, praziquantel is apparently effective for treatment of cases infected with *Spirometra* spp. The recommended dose is 120-150 mg/kg body weight, over a 2-day period<sup>[1,74,75]</sup>. On the other hand, for cases of *S. proliferum*, praziquantel is ineffective and surgical removal is the only effective treatment<sup>[75]</sup>.

**Conclusion:** Four species of *Spirometra* and the aberrant *S. proliferum* are incriminated in causing human infections. Other species reported to infect humans in the literature are probably synonymous. Human sparganosis is still persistently endemic in many parts of the world. Moreover, cases are being detected more often. Thus, sparganosis should be considered as an emerging human parasitic infection. Despite the considerable importance and the emerging state, human sparganosis is among the most neglected human parasitoses.

### REFERENCES

- John DT, Petri WA, Jr. Markell and Voge's Medical Parasitology. 9<sup>th</sup> ed. Philadelphia, PA: W. B. Saunders; 2006.
- Kuchta R, Scholz T, Brabec J, Narduzzi-Wicht B. *Diphyllobothrium*, *Diplogonoporus*, and *Spirometra*. In: Xiao L, Ryan U, Feng Y, editors. Biology of foodborne parasites. Boca Raton, FL: CRC Press 2015; 299-326.
- Kwon SY, Rhee SK, Lee HS, Kim KW, Chae Y. Sparganosis in subcutaneous tissue of thigh: A case report. J Korean Orthop Assoc 1998; 33(1): 207-210.
- Kim JI, Kim TW, Hong SM, Moon TY, Lee IS, Choi KU, et al. Intramuscular sparganosis in the gastrocnemius muscle: A case report. Korean J Parasitol 2014; 52(1): 69-73.
- Park WH, Shin TY, Yoon SM, Park SH, Kang YJ, Kim DK, et al. A case report of testicular sparganosis misdiagnosed as testicular tumor. J Korean Med Sci 2014; 29(7): 1018-1020.
- Yu MH, Chen CL, Liu XL, Xu XW. Differential diagnosis of a carcinoma of the maxillary sinus that resembles a *Sparganum* infection: A case report. Exp Ther Med 2015; 10(4): 1324-1326.
- Nithiuthaia S, Anantaphrutib MT, Waikagulb J, Gajadharc A. Waterborne zoonotic helminthiasis. Vet Parasitol 2004; 126: 167-193.
- Wiwanitkit V. A review of human sparganosis in Thailand. Int J Infect Dis 2005; 9(6): 312-316.
- Shin EH, Guk SM, Kim HJ, Lee SH, Chai JY. Trends in parasitic diseases in the Republic of Korea. Trends Parasitol 2008; 24(3): 143-150.
- Li MW, Song HQ, Li C, Lin HY, Xie WT, Lin RQ, et al. Sparganosis in mainland China. Int J Infect Dis 2011; 15(3): e154-156.
- Mueller JF. A repartition of the genus *Diphyllobothrium*. J Parasitol 1937; 23: 308-310.
- Faust EC, Campbell HE, Kellogg CR. Morphological and biological studies on the species of *Diphyllobothrium* in China. Am J Hyg 1929; 9(3): 560-583.
- Schmidt GD. CRC handbook of tapeworm identification. Boca Raton, FL: CRC Press; 1986.
- Okamoto M, Iseto C, Shibahara T, Sato MO, Wandra T, Craig PS, et al. Intraspecific variation of *Spirometra erinaceieuropaei* and phylogenetic relationship between *Spirometra* and *Diphyllobothrium* inferred from mitochondrial CO1 gene sequences. Parasitol Int 2007; 56(3): 235-238.
- Wijesundera MS, Ratnatunga N, Kumarasinghe MP, Dissanaikae AS. First reports of subcutaneous sparganosis in Sri Lanka. Ceylon Med J 1997; 42(1): 30-32.
- Sambon B. 1. Descriptions of some new species of animal parasites. Proc Zool Soc Lond 1907; 77(2): 282-283.
- de Meillon B, Leech RB. A sparganum from an East African native. S Afr Med J 1943; 17(18):289-290.
- Alves WD, Gelfand M, Weinberg R. A case of sparganosis in an African from Portuguese East Africa. Trans R Soc Trop Med Hyg 1954; 48(1): 87-88.
- Fain A, Piraux A. Sparganosis in man and animals in Ruanda-Urundi. Bull Soc Pathol Exot Filiales 1959; 52: 804-808.
- Nelson GS, Pester FR, Rickman R. The significance of wild animals in the transmission of cestodes of medical importance in Kenya. Trans R Soc Trop Med Hyg 1965; 59(5): 507-524.
- Schmid H, Watschinger H. Sparganosis in the Masailand. Acta Trop 1972; 29(3): 218-230.
- Eberhard ML, Thiele EA, Yembo GE, Yibi MS, Cama VA, Ruiz-Tiben E. Thirty-seven human cases of sparganosis from Ethiopia and South Sudan caused by *Spirometra* spp. Am J Trop Med Hyg 2015; 93(2): 350-355.
- Read CP. Human sparganosis in South Texas. J Parasitol 1952; 38(1): 29-31.
- Brooks TJ, Jr, Hutchison WF, Safley TJ, Ross TG. Human sparganosis in Mississippi: report of two cases. Am J Trop Med Hyg 1960; 9: 192-194.
- Leon LA, Almeida R, Mueller JF. A case of ocular sparganosis in Ecuador. J Parasitol 1972; 58(1): 184-185.

26. Mueller JF, Froes OM, Fernandez TR. On the occurrence of *Spirometra mansonoides* in South America. *J Parasitol* 1975; 61(4): 774-775.
27. Cho C, Patel SP. Human sparganosis. In northern United States. *N Y State J Med* 1978; 78(9): 1456-1458.
28. Mitchell A, Scheithauer BW, Kelly PJ, Forbes GS, Rosenblatt JE. Cerebral sparganosis. Case report. *J Neurosurg* 1990; 73(1): 147-150.
29. Kron MA, Guderian R, Guevara A, Hidalgo A. Abdominal sparganosis in Ecuador: a case report. *Am J Trop Med Hyg* 1991; 44(2): 146-150.
30. Pujatti D. Un caso di sparganosi umana. *Riv Parassitol* 1953; 14: 213-217.
31. Rossi G, Genesi M. Pseudotumori parassitari. *Minerva Med* 1953; 44:1517-1525.
32. Bianchi L. Sparganosi umana. Osservazione sopra un caso autoctono in Alta Italia. *Proc First Intern Congr Parasitol* 21-26 Sept. Rome, Italy; 1964; 820-822.
33. Monolo L, Pontiggia M, Tarfani A, Doriggi A. Su di un caso di sparganosi cerebrale. *Riv Neurobiol* 1976; 22: 69-75.
34. Garin YJF, Frottier J, Laverigne-Slove A, Houdart R, Poirot JL. Cutaneous sparganosis in France: the second case described from Europe. *APMIS* 1997; 105(1): 14-16.
35. Mougeot G, Cambon M, Menerath JM, Dimeglio V, Houin R. Human eye anterior chamber sparganosis. *Parasite* 1999; 6(4): 365-367.
36. Pampiglione S, Fioravanti ML, Rivasi F. Human sparganosis in Italy. Case report and review of the European cases. *APMIS* 2003; 111(2): 349-354.
37. Iwata S. Experimental and morphological studies of Manson's tapeworm, *Diphyllobothrium erinacei* (Rudolphi). Special reference with its scientific name and relationship with *Sparganum proliferum Iijima*. In: Morishita K, Komiya Y, Matsubayashi H, editors. *Progress of Medical Parasitology in Japan*. Tokyo, Japan: Meguro Parasitological Museum Press; 1972; 536-590.
38. Beaver PC, Jung RC, Cupp EW. *Clinical Parasitology* 9<sup>th</sup> ed. Philadelphia, PA: Lea & Febiger. 1984.
39. Ishii H, Mukae H, Inoue Y, Kadota JI, Kohno S, Uchiyama F, *et al.* A rare case of eosinophilic pleuritis due to sparganosis. *Intern Med* 2001; 40: 783-785.
40. Nobayashi M, Hirabayashi H, Sakaki T, Nishimura F, Fukui H, Ishizaka S, *et al.* Surgical removal of a live worm by stereotactic targeting in cerebral sparganosis. Case report. *Neurol Med Chir (Tokyo)*. 2006; 46(3): 164-167.
41. Garcia L, Bruckner DA. *Diagnostic Medical Parasitology*. 5th ed. Herndon, VA: ASM Press. 2007.
42. Yang JW, Lee JH, Kang MS. A case of ocular sparganosis in Korea. *Korean J Ophthalmol*. 2007; 21(1): 48-50.
43. Wiwanitkit V. Ocular sparganosis. *Orbit* 2014; 33(6): 474-474.
44. Nath R, Gogoi RN. Ocular sparganosis from Assam. *Trop Parasitol* 2015; 5(1): 64-67.
45. Faust EC, Beaver PC, Jung RC. *Animal agents and vectors of human disease*. Philadelphia, PA: Lea & Febiger; 1975.
46. Yamaguti S. *Systema Helminthum*. New York, NY: Interscience Publishers Inc.; 1959.
47. Faust EC, Wassel M. Preliminary survey of the intestinal parasites of man in the central Yangtze valley. *China Med J* 1921; 35: 532-561.
48. Suzuki N, Kumazawa H, Hosogi H, Nakagawa O. A case of human infection with the adult of *Spirometra erinacei* (Rudolphi, 1819) Faust, Campbell and Kellogg, 1929. *Jpn J Parasitol* 1982; 31: 23-26.
49. Lee SH, Chai JY, Seo BS, Cho SY. Two cases of human infection by adult of *Spirometra erinacei*. *Kisaengchunghak Chapchi* 1984; 22(1) :66-71.
50. Jeon HK, Park H, Lee D, Choe S, Kim KH, Huh S, *et al.* Human infections with *Spirometra decipiens* plerocercoids identified by morphologic and genetic analyses in Korea. *Korean J Parasitol* 2015; 53(3): 299-305.
51. Eom KS, Park H, Lee D, Choe S, Kim KH, Jeon HK. Mitochondrial genome sequences of *Spirometra erinacei* and *S. decipiens* (Cestoidea: Diphylobothriidae). *Korean J Parasitol* 2015; 53(4): 455-463.
52. Jeon HK, Park H, Lee D, Choe S, Kim KH, Sohn WM, *et al.* Genetic identification of *Spirometra decipiens* plerocercoids in terrestrial snakes from Korea and China. *Korean J Parasitol* 2016; 54(2): 181-185.
53. Mueller JF, Coulston F. Experimental human infection with the sparganum larva of *Spirometra mansonoides* (Mueller, 1935). *Am J Trop Med Hyg* 1941; 21(3): 399-425.
54. Mueller JF. The biology of *Spirometra*. *J Parasitol* 1974; 60(1): 3-14.
55. Lee SU, Huh S, Phares CK. Genetic comparison between *Spirometra erinacei* and *S. mansonoides* using PCR-RFLP analysis. *Korean J Parasitol* 1997; 35: 277-282.
56. Opuni EK, Muller RL. Studies on *Spirometra theileri* (Baer, 1925) n. comb. 1. Identification and biology in the laboratory. *J Helminthol* 1974; 48(1): 15-23.
57. Nakamura T, Hara M, Matsuoka M, Kawabata M, Tsuji M. Human proliferative sparganosis. A new Japanese case. *Am J Clin Pathol* 1990; 94(2): 224-228.
58. Miyadera H, Kokaze A, Kuramochi T, Kita K, Machinami R, Noya O, *et al.* Phylogenetic identification of *Sparganum proliferum* as a pseudophyllidean cestode by the sequence analyses on mitochondrial COI and nuclear sdhB genes. *Parasitol Int* 2001; 50(2): 93-104.
59. Iijima I. On a new cestode larva parasitic in man (Plerocercoides prolifer). *J Coll Sci Imp Univ Tokyo* 1905; 20: 1-21.
60. Mueller JF. Studies on *Sparganum mansonoides* and *Sparganum proliferum*. *Am J Trop Med* 1938; 18: 303-324.
61. Lin TP, Su IJ, Lu SC, Yang SP. Pulmonary proliferative sparganosis. *J Form Med Assoc* 1978; 77: 467-472.
62. Beaver PC, Rolon FA. Proliferating larval cestode in a man in Paraguay. A case report and review. *Am J Trop Med Hyg* 1981; 30(3): 625-637.
63. Noya O, Alarcon de Noya B, Arrechdera H, Torres J, Arguello C. *Sparganum proliferum*: an overview of its structure and ultrastructure. *Int J Parasitol* 1992; 22(5): 631-640.
64. Qiu MH, Qiu MD. Human plerocercoidosis and sparganosis: I. A historical review on aetiology. *Chin J Parasitol Parasit Dis* 2009; 27(1): 54-60.
65. Moulinier R, Martinez E, Torres J, Noya O, de NBA, Reyes O. Human proliferative sparganosis in Venezuela: Report of a case. *Am J Trop Med Hyg* 1982; 31(2): 358-363.

66. MERIC R, ILIE MI, HOFMAN V, RIOUX-LECLERCQ N, MICHOT L, HAFFAF Y, *et al.* Disseminated infection caused by *Sparganum proliferum* in an AIDS patient. *Histopathology* 2010; 56(6): 824-828.
67. CONNOR DH, SPARKS AK, STRANO AJ, NEAFIE RC, JUVELIER B. Disseminated parasitosis in an immunosuppressed patient. Possibly a mutated sparganum. *Arch Pathol Lab Med* 1976; 100(2): 65-68.
68. LUCAS SB, HASSOUNAH OA, DOENHOFF M, MULLER R. Aberrant form of *Hymenolepis nana*: possible opportunistic infection in immunosuppressed patients. *Lancet* 1979; 2(8156-8157): 1372-1373.
69. OLSON PD, YODER K, FAJARDO LGL, MARTY AM, VAN DE PAS S, OLIVIER C, *et al.* Lethal invasive cestodiasis in immunosuppressed patients. *J Infect Dis* 2003; 187(12): 1962-1966.
70. BROGLIA A, KAPEL C. Changing dietary habits in a changing world: Emerging drivers for the transmission of foodborne parasitic zoonoses. *Vet Parasitol* 2011; 182(1): 2-13.
71. LIU Q, LI MW, WANG ZD, ZHAO GH, ZHU XQ. Human sparganosis, a neglected food borne zoonosis. *Lancet Infect Dis* 2015; 15(10): 1226-1235.
72. ALI-KHAN Z, IRVING RT, WIGNALL N, BOWMER EJ. Imported sparganosis in Canada. *Can Med perspective for control. Trends Parasitol* 2008; 24(4): 190-196.
73. PHUNMANEE A, BOONSAWAT W, INDHARAPOKA B, TUNTISIRIN C, KULARBKEAW J. Pulmonary sparganosis: a case report with five years follow-up. *J Med Assoc Thai* 2001; 84(1): 130-135.
74. LIN XM, LIU CJ, ZHANG HW, ZHENG LY, YAN QY, HE LJ, *et al.* Epidemiological investigation on sparganosis *mansonii* and animal experiments. *Zhongguo Ji Sheng Chong Xue Yu Ji Sheng Chong Bing Za Zhi*. 2010; 28(2): 132-134.
75. TORRES JR, NOYA OO, NOYA BA, MOULINIÈRE R, MARTINEZ E. Treatment of proliferative sparganosis with mebendazole and praziquantel. *Trans R Soc Trop Med Hyg* 1981; 75(6): 846-847.